

Second-generation Platelet Concentrate (Platelet-rich Fibrin) as a Scaffold in Regenerative Endodontics: A Case Series

Hengameh Bakhtiar, DDS, MSc, DoIBoE,* Shabram Esmaeili, MD,*
Setareh Fakhr Tabatabayi, DDS,* Mohammad Reza Ellini, BC Bio,*
Mohammad Hossein Nekoofar, DDS, MSc, DoIBoE, PhD,†‡
and Paul M.H. Dummer, BDS, MScD, PhD, DDDSc, FDSRCS(Ed), FHEA‡

Abstract

Introduction: The purpose of this case series was to report the clinical and radiographic results of a pulp regenerative procedure using platelet-rich fibrin (PRF), a second-generation platelet concentrate, in immature teeth with necrotic pulps. **Methods:** Root canal revascularization using PRF was performed on 4 immature teeth with necrotic pulps. After access cavity preparation, the root canals were irrigated with low concentration sodium hypochlorite solution (1.5% sodium hypochlorite [20 mL/canal, 5 minutes]) and then irrigated with saline (20 mL/canal, 5 minutes). Equal proportions (167 mg) of ciprofloxacin, metronidazole, and cefaclor were mixed and diluted to a final concentration of 1 g/mL. Finally, the canal was sealed with 3–4 mm of a temporary restorative material, and patients were dismissed for 2 to 3 weeks. At the second appointment, 9 mL of the patient's whole blood was obtained and centrifuged to prepare a PRF clot. Canals were irrigated with 17% EDTA, and a sharp spreader was inserted beyond the apex. Then, the PRF clot was placed inside the root canals, and Biodentine (Septodont, Saint-Maur, France) was placed directly over the PRF. The teeth were restored permanently with glass ionomer cement and composite resin. **Results:** Clinical examinations revealed that all cases were asymptomatic at the recall appointments at 1, 3, 6, 12, and 18 months. Radiographs revealed resolution of the periapical lesions, further root development, and apical closure in all cases. **Conclusions:** On the basis of the short-term results up to 12 months, PRF clots acted as successful scaffolds for the regeneration of pulpal contents in immature teeth with necrotic pulps. (*J Endod* 2016; ■:1–8)

Key Words

Open apex, platelet-rich fibrin, regenerative endodontics, revascularization, second-generation platelet concentrate

Endodontic treatment of immature teeth with necrotic pulps is challenging because of the thin dentinal walls of the roots and their susceptibility to fracture (1). Historically, calcium hydroxide was used for apexification of such teeth, but long-term calcium hydroxide treatment may disrupt the links between collagen fibers and hydroxyapatite crystals, which results in reduced micro-hardness and increased susceptibility to fracture (2–5). To overcome the drawbacks of calcium hydroxide apexification, 1-step apical closure techniques using mineral trioxide aggregate (MTA) were introduced (2). However, in this technique the root length and thickness of dentinal walls remains unchanged (6). Regenerative procedures are a feasible option for treatment of immature teeth with necrotic pulps especially since further development of the root apex and increased thickness of root walls are expected (7). In the past two decades, several reports have described clinical and radiographic evidence of successful regenerative procedures for treatment of such teeth (8). Induced bleeding and blood clots are integral parts of these procedures as they provide an appropriate scaffold and sufficient stem cells (9, 10). Platelet-rich plasma (PRP) has also been recommended as a potential scaffold for regenerative endodontic treatments (11, 12).

It has been shown that stimulated platelets release secretory granules that contain a variety of growth factors (13). PRP releases growth factors rapidly within 7 to 14 hours, which then declines (13). A second-generation platelet concentrate, platelet-rich fibrin (PRF), was developed by Choukroun et al (14). PRF has high concentrations of fibrin clots; no supplementary thrombin is needed during its preparation. PRF is formed during a gradual polymerization protocol that incorporates a higher concentration of cytokines into fibrins (13). Therefore, growth factors meshed in these fibrins are released more slowly between 7 and 14 days (13). In this case series, a regenerative procedure using PRF was performed on 4 immature single-rooted teeth

Significance

Endodontic treatment of immature teeth with necrotic pulps is challenging. Platelet-rich fibrin blood clots are suggested as a feasible alternative for regenerative endodontic protocols.

From the *Dental Material Research Center, Tehran Dental Branch, Islamic Azad University, Tehran, Iran; †Department of Endodontics, School of Dentistry, Tehran University of Medical Sciences, Tehran, Iran; and ‡Endodontology Research Group, School of Dentistry, College of Biomedical and Life Sciences, Cardiff University, Cardiff, UK.

Address requests for reprints to Dr Mohammad Hossein Nekoofar, School of Dentistry, Cardiff University, Cardiff CF10 3XQ, UK. E-mail address: Nekoofarmh@cardiff.ac.uk

0099-2399/\$ - see front matter

Copyright © 2016 American Association of Endodontists.

<http://dx.doi.org/10.1016/j.joen.2016.10.016>

Regenerative Endodontics

with pulp necrosis and then evaluated clinically and radiographically for up to 12 months.

Case Reports

Case Report 1

A 9-year-old female presenting with an acute apical abscess with a history of avulsion of an immature maxillary left central incisor was referred to a private endodontic practice. The first practitioner had provided a nonrigid splint for 10 days and performed a pulpectomy using nonsetting calcium hydroxide paste as a medicament. The patient had a normal medical history. The tooth was not discolored; periodontal probing depths of the maxillary incisors were within the normal limit, and was between 3 and 4 mm. Additionally, the tooth was not responsive to cold and electric pulp tests.

Radiographic examination revealed an immature root with an open apex but no evidence of periapical rarefaction (Fig. 1A). Regen-

erative endodontic treatment was initiated after obtaining consent from parents.

After obtaining profound anesthesia with 2% lidocaine with 1:80,000 epinephrine (Darupakhsh, Tehran, Iran), the tooth was isolated with a rubber dam and the access cavity modified. The working length of each canal was determined using an electronic root canal length measurement device (Root ZX; J Morita MFQ, Kyoto, Japan) confirmed by taking a digital periapical radiograph (Soredex, Tuusula, Finland). The root canal was irrigated copiously with 20 mL 1.5% sodium hypochlorite (NaOCl) solution for 5 minutes with a 23-G side-opened needle (Optimus, São Paulo, SP, Brazil) followed by 20 mL normal saline for 5 minutes (15). A limited amount of filing with #40 H-files (Mani; Utsunomiya, Tochigi, Japan) was performed in order to disrupt the biofilm and roughen the dentinal walls without widening the canal. The canal was then dried with paper points. The internal walls of the pulp chamber were sealed with a dentin-bonding agent (3M ESPE Dental Products, St Paul, MN) to minimize the risk of staining. Then,

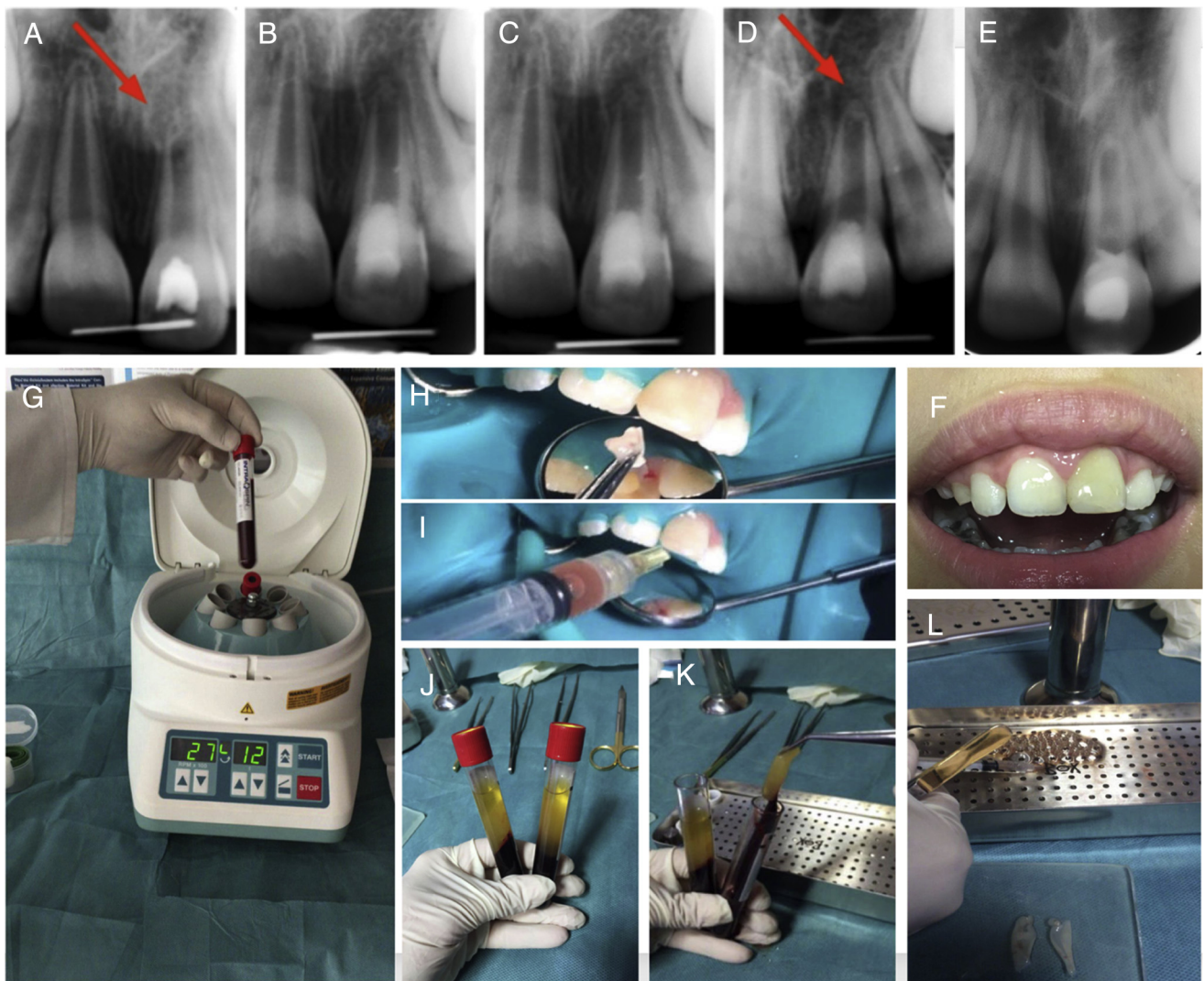


Figure 1. (A) A 9-year-old girl with a history of avulsion of the left maxillary central incisor with a periapical abscess and a necrotic tooth with an open apex (red arrow). Radiographs taken at the (B) 1-month, (C) 3-month, and (D) 6-month follow-ups revealed signs of appreciable complete apical closure after 6 months (red arrow). (E) The 18-month follow-up indicated further apical closure. (F) Minimal discoloration after 18 months was noticeable. (G) The sterile tubes were centrifuged at 2700 rpm for 12 minutes. (H) The small pieces of PRF clot were placed in the root canal. (I) The root canal was irrigated with the liquid in which the PRF clot was floated. (J and K) Three parts were formed in tubes, and the intermediate layer of PRF clot was collected. (L) The PRF clot was rolled over on itself on the glass slab. The small piece of wire placed in the radiographs are intended for measurement software calibrations.

equal proportions of ciprofloxacin (167 mg) (Aria, Tehran, Iran), metronidazole (tablet, 167 mg) (Daroopaksh, Tehran, Iran), and cefaclor (capsule, 167 mg) (Losefar; Zentiva Co, Istanbul, Turkey) were crushed and mixed with 0.50 mL normal saline to form a creamy mixed dressing (1 g/mL) (16). Before crushing, the sugar coatings on the tablets were removed. The triple antibiotic mixture was inserted into the canal with a syringe (Centrix Inc, Shelton, CT) while ensuring that the mixture remained below the cemento-enamel junction. The pulp chamber was then filled with 3–4 mm of Cavit (3M ESPE Dental Products), and the patient was dismissed for 2 to 3 weeks.

At the second appointment, the patient was asymptomatic, and the tooth was anesthetized using 3% mepivacaine without vasoconstrictor. After application of a rubber dam, the access cavity was reopened, the antibiotic mixture was washed out with 20 mL 17% EDTA (Sigma-Aldrich, St Louis, MO), and the root canal was dried with paper points (17). Bleeding was induced by inserting a #20 sharp spreader (Dentsply Tulsa Dental, Tulsa, OK) beyond the apex. For the PRF preparation, 9 mL of the patient's whole blood was collected in sterile tubes from the cubital vein. The tubes were centrifuged for 12 minutes with a speed of 2700 rpm (Intra-Lock International, Boca-Raton, FL) (Fig. 1G). Three layers were formed inside each test tube: a base layer containing erythrocytes, an intermediate layer of PRF clot, and a surface layer of acellular plasma. The PRF clot was separated from the other layers (Fig. 1J) and then compressed in a PRF box (Fig. 1K) (Intra-Lock International). The

compressed PRF membrane was rolled over itself (Fig. 1L) to allow its implantation into the canal (Fig. 1H). The liquid that was obtained by compression of the PRF clot was used to irrigate the root canal (Fig. 1I). The PRF membrane was inserted inside the root canal and condensed apically with an endodontic hand plugger (Fig. 1H). The access cavity was double sealed with Biodentine (Septodont, Saint-Maur, France) and injectable light cure glass ionomer cement (GC America: GC Fuji Filling LC, Alsip, IL) while ensuring that Biodentine remained below the cemento-enamel junction. Indeed, PRF also facilitated the accurate placement of Biodentine so that the Biodentine was not in contact with the blood clot and irrigations. The tooth was asymptomatic at the 1-, 3-, and 6-month follow-ups. Parallel radiographic examination revealed no periapical lesion at the 1-month follow-up (Fig. 1B). Furthermore, the initiation of apical closure was obvious by the 3-month follow-up (Fig. 1C). Signs of apical closure were observed after 6 months (Fig. 1D). Thickening of dentinal walls and complete apical closure were noted over 18 months (Fig. 1E). The 18-month follow-up showed signs of minimal discoloration (Figs. 1F and 2).

Case Report 2

An 18-year-old woman was referred with a cosmetic complaint associated with a maxillary right lateral incisor (Fig. 3A). The tooth was not responsive to electric pulp testing and cold stimulation and

	Case 1	Case 2	Case 3	Case 4
Clinical Examination after 18 month follow up				
Response to cold thermal pulp test	×	×	×	×
Response to electric pulp test	×	×	×	×
Tenderness to percussion	×	×	×	×
Tooth mobility	×	×	×	×
Ankylotic percussion tone	×	×	×	×
Pain on palpation	×	×	×	×
Swelling	×	×	×	×
Sinus tract	×	×	×	×
Coronal discoloration	×	×		
Probing depth	2-3mm	2-3mm	2-3mm	2-3mm
Cracks	×	×	×	×
Radiographic Analysis During one year follow up				
Periapical lesion	×	×	×	×
Apical Closure accrued after	6 months	6 months	12 months in left incisor & not accrued in right	18months
Root Thickening accrued after	12 months	9 months	18 months	18 months

Figure 2. The flowchart for clinical and radiographic diagnostics tests (after 18 months).

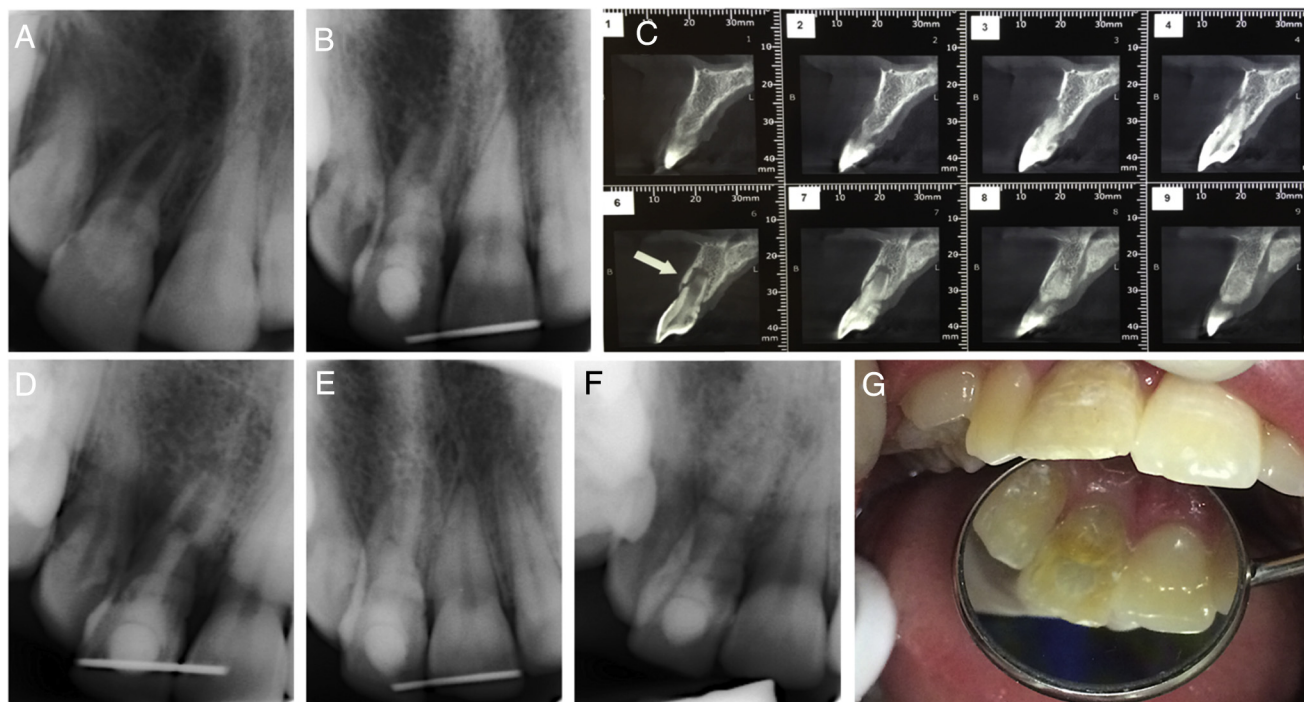


Figure 3. (A) A radiographic view of a right lateral incisor with the diagnosis of dens invagination. (B) The 1-month follow-up revealed progression in root development. (C) The preoperative radiographic examination (cone-beam computed tomographic imaging) revealed an immature tooth with an open apex and labial bone resorption (*arrow* in the 6th section). (D and E) The 3- and 6-month follow-ups showed thickening of the dentinal walls and apical closure. (F) The 18-month follow-up indicated further apical closure dentinal wall thickening. (G) The 18-month follow-up also showed minimal discoloration.

was not tender to percussion or palpation. A primary diagnosis was made of Oehler class II dens invagination. The radiographic examination cone-beam computed tomographic imaging revealed an immature tooth with a necrotic pulp and open apex with labial bone resorption. Written consent was obtained, and a regeneration procedure was performed using PRF as described in case 1. At the 1-, 3-, 6-, and 18-month follow-ups, thickening of dentinal walls and progression of root formation were observed (Fig. 3A–G). The 18-month follow-up shows minimal signs of discoloration (Figs. 2 and 3G).

Case Report 3

A 9-year-old female was referred with a history of recurrent swelling on the anterior maxillary buccal mucosa and pulpectomy of maxillary central incisors. Examination and radiographic evaluation revealed a history of amelogenesis imperfecta and immature maxillary central incisors (Fig. 4A). The clinical appearance of central incisors indicated extensive discoloration, recurrent carries, and a history of recurrent abscess (Fig. 4B). The patient's medical history was not relevant. Clinical examination revealed no sensitivity to cold and electric pulp test, and the central incisors did not respond to palpation or percussion. The treatment protocol described previously was performed on the maxillary central incisors, and the patient returned 1, 6, 12, and 18 months later (Fig. 4C–F). Radiographic examinations revealed a decrease in apical lesion size after 3 months (Fig. 4D). The 12-month follow-up indicated a reduction in lesion size but it did not completely disappear (Fig. 4E). The 18-month follow-up examinations revealed progressive loss of lesion (Fig. 4F), but the apical closure was not complete even after 18 months in the maxillary right incisor. The clinical appearance after reconstruction of the central incisors compared with their initial appearance (Fig. 4B) is shown in Figures 2 and 4G.

Case Report 4

A 7-year-old male was referred with a history of trauma and intrusion of a right maxillary central incisor 3 months before his appointment. The medical history was noncontributory. The patient did not have a history of drugs used before treatment. The extraoral examination showed no significant changes. The intraoral examination revealed a sinus tract, diffuse swelling, and pus discharge through the labial and grade 2 mobility (Fig. 5A and B). The tooth did not respond to either cold or electric pulp tests. However, the pulp of the left maxillary central incisor had a normal response to cold and electric pulp tests. Radiographic and clinical examination revealed an immature tooth with a necrotic pulp with an open apex and a small periapical lesion associated with the maxillary right incisor (Fig. 5A). Therefore, a diagnosis of an immature tooth with a necrotic pulp with chronic apical abscess was confirmed.

An access cavity was prepared on the right maxillary central incisor (Fig. 5C). Discharge continued after access cavity preparation, and on entry to the root canal, purulent hemorrhagic drainage was noted (Fig. 5D). The treatment protocol was performed as described in the previous cases. At the second appointment, the sinus tract had completely disappeared, and 6 months later, the tooth was completely erupted and was level with the adjacent teeth; there were also signs of continued root apex development (Fig. 5E and F). At the 9-month recall, apical closure was observed (Fig. 5G). Examination at the 18-month follow-up revealed complete apex development (Fig. 5I) and minimal signs of discoloration (Fig. 5H and J). Even though the adjacent left maxillary incisor revealed no evidence of apical closure, it remained responsive to cold and electric pulp tests and there was no pain on percussion (Fig. 2).

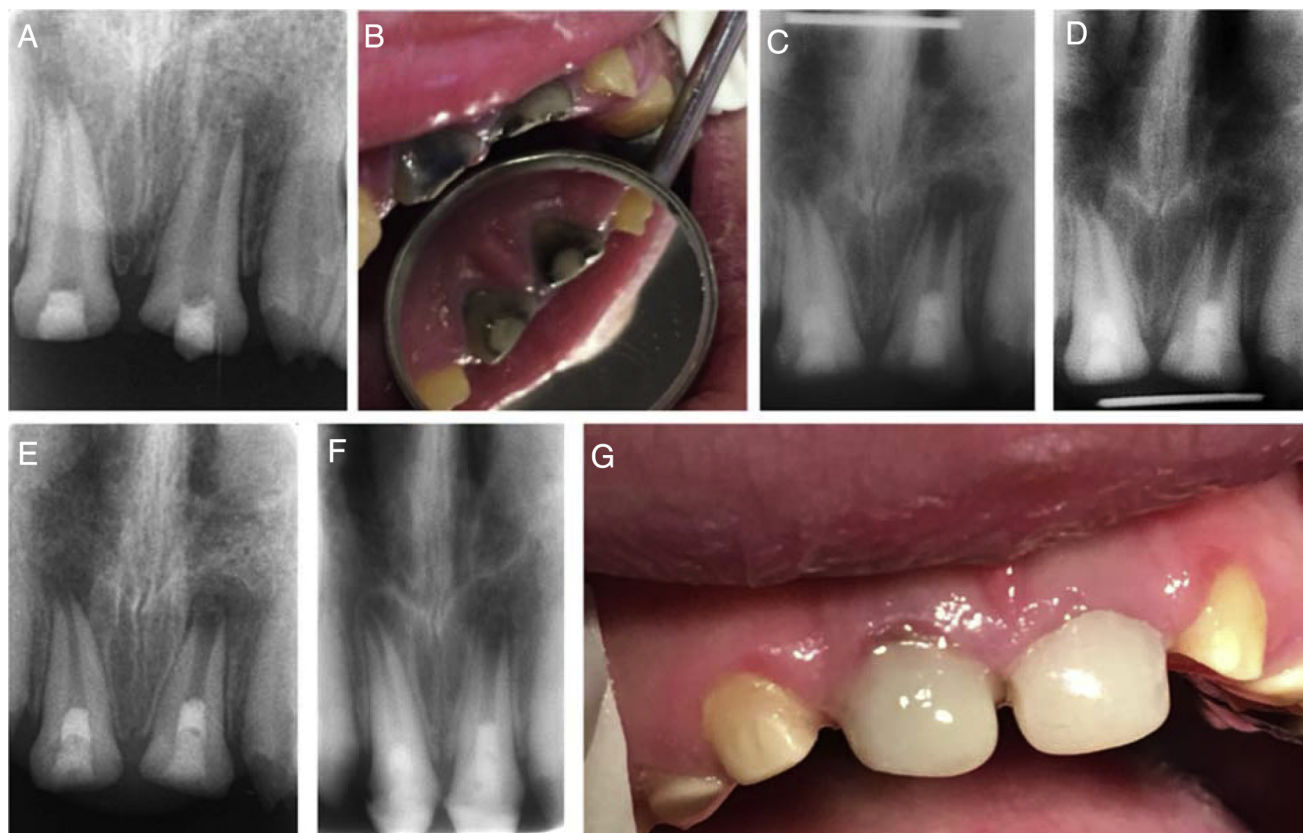


Figure 4. (A) The initial radiograph of the case with pulpectomy of the maxillary centrals. (B) The clinical appearance before treatment of the maxillary incisors. (C) The 1-month follow-up radiograph. (D) The 3-month follow up radiograph indicated a reduction of the initial periapical lesion. (E) The radiograph at 12 months revealed indications of apical closure. (F) The 18-month follow-up revealed thickening of the lateral dentinal walls in the maxillary right incisor and appreciable apical closure in the maxillary left incisor, but the apical closure was not complete even after 18 months in the maxillary right incisor. (G) The clinical appearance after reconstruction of the maxillary incisors after 18 months.

Discussion

Disinfection of the root canal system is a crucial step in regenerative endodontic procedures. The irrigants used should be selected on the basis of their bactericidal/bacteriostatic properties and their ability to promote survival and proliferation of stem cells (18). Thus, in this case series, the irrigant was 1.5% NaOCl (20 mL/canal, 5 minutes) followed by irrigation with saline (20 mL/canal, 5 minutes). The irrigating needle was positioned 1 mm or so from the root end to minimize cytotoxicity to stem cells in the apical tissues (19, 20). Higher concentrations of NaOCl are toxic to stem cells from apical papilla (SCAPs), whereas lower concentrations of NaOCl may be used as an irrigant because of its limited cytotoxic effects on human bone marrow mesenchymal stem cells (21).

Mechanical instrumentation is not recommended in immature teeth because of their thin dentinal walls (22). However, without application of mechanical instrumentation, a biofilm may remain and be more resistant to antibacterial agents compared with limited filing of the canal walls (19). Therefore, in this case series, gentle filing was performed in an attempt to disrupt the biofilm and thus achieve maximum permeation of antimicrobial agents.

Various combinations of antibiotics have been proposed but the most widely used is a triple antibiotic paste (ciprofloxacin, metronidazole, and minocycline). In this case series, minocycline was replaced with cefaclor to minimize tooth discoloration (20). Indeed, as evident in the 18-month follow-up photographs (Figs. 1F, 3G, 4G, and 5H and J), none of our 4 cases showed a bluish discoloration. Previous studies

recommended a 2- to 6-week interval between the first and second appointments (23); however, it has been shown that long-term exposure (1–3 months) to triple antibiotic paste and double antibiotic paste may decrease dentin microhardness (4, 5, 24). Therefore, in this case series, diluted triple antibiotic paste was retained inside the root canal system for only 3 weeks. The applied dose (1 g/mL) was not in accordance with the American Association of Endodontist's clinical considerations for a regenerative procedure, which recommends a concentration of 0.1 mg/mL (22). Clinical application of this low concentration is difficult. The American Association of Endodontist's recommendation is probably based on the results of laboratory studies that reported that drug concentrations of more than 100 μ g/mL are cytotoxic to SCAPs and dental pulp stem cells (25). In addition, Netea et al (26) showed that stem cells do not survive when placed in contact with previously treated dentin with triple antibiotic paste at a concentration of 1 g/mL. However, antibiotics tend to lose their effectiveness when in contact with the dentin complex (27). In addition, although reducing the concentration of antibiotics decreases their potential cytotoxicity; it will also dramatically reduce their antimicrobial efficacy. Thus, a balanced concentration should be used to accomplish effective disinfection but with low cytotoxicity (19, 28).

At the second appointment, application of 17% EDTA for removal of the residual diluted triple antibiotic paste is recommended (16). EDTA releases growth factors from dentinal walls, which can lead to proliferation and differentiation of stem cells (7). Using EDTA may also affect the survivability of SCAPs (23).

Regenerative Endodontics

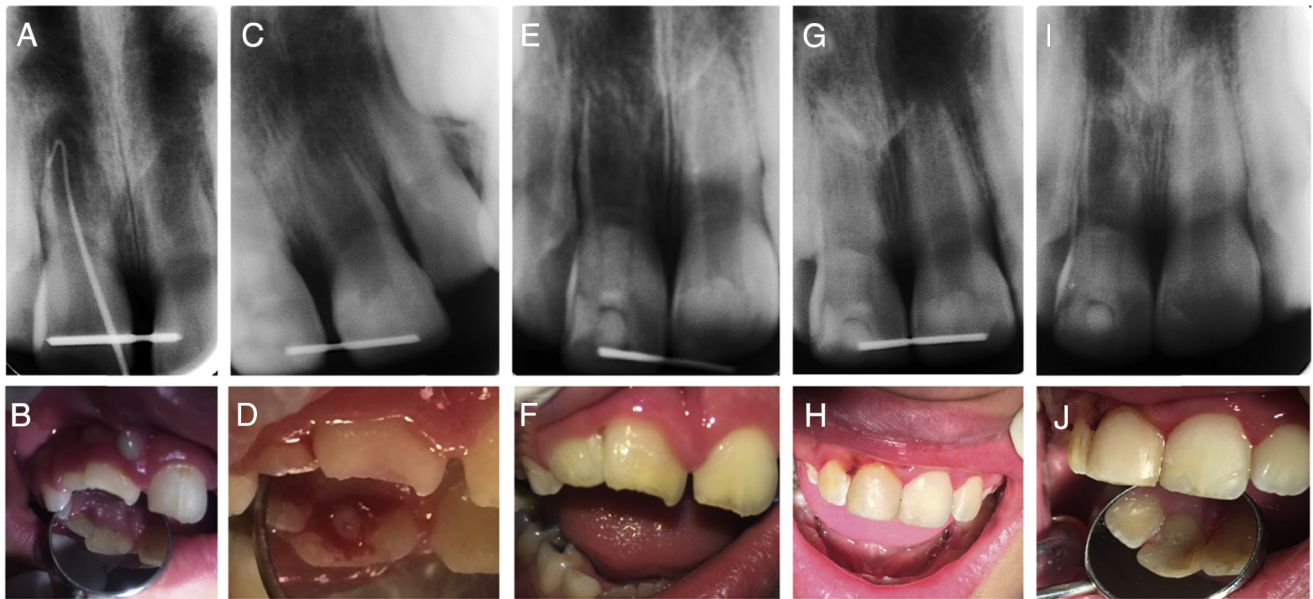


Figure 5. (A and B) A 7-year-old boy with immature necrotic tooth with chronic apical abscess of the right maxillary central incisors. Intraoral examinations showed a sinus tract and diffuse swelling and pus discharge through the labial sinus. (C and D) Pus discharge after access cavity preparation. (E and F) Radiographs after 6 months showed complete eruption of the tooth, and it was level with the adjacent teeth; there were signs of continued development of the apex. (G) At the 9-month recall, apical closure was observed. (I) The 18-month follow-up radiograph showed further apical closure and near complete apex development. (H and J) The 18-month follow-up showed minimal signs of discoloration.

Regenerative endodontic procedures are possible using application of the principles of tissue engineering, which requires spatial orientation of stem cells, signaling molecules, and a scaffold (23). Thibodeau et al (29) reported that revascularization with a blood clot scaffold produced satisfactory results in animal samples. Lovelace et al (30) reported that collected evoked blood from inside the root canal contained up to 600-fold accumulation of CD73 and CD105 (markers of mesenchymal stem cells) in comparison with systemic blood. Nevertheless, this procedure may cause discomfort for the patient while mechanically irritating the periapical tissues (31); furthermore, the formation of a blood clot is sometimes difficult. For instance, when calcium hydroxide is used between treatment sessions, coagulation necrosis may occur (32). Extra efforts for evoking bleeding may also damage the Hertwig epithelial root sheath, which is a crucial element for root development. Consequently, damage to this structure may result in no further root development or formation of blunted root tips (33, 34). Therefore, in this series of cases, bleeding was induced with the aid of a sharp spreader without lateral or circumferential movements (23).

A collagen pad has been suggested as a scaffold for regenerative endodontic procedures (35). Biologically, collagen is inactive, contains no growth factors, and does not have a significant role in stimulating cell proliferation (29). Platelet concentrates are an interesting source of growth factors that have been used for enhancing the regeneration of various tissue defects including dentin and the dentin-pulp complex. Platelets are rich in growth factors and cytokines (eg, platelet-derived growth factor, transforming growth factor beta, vascular endothelial growth factor, interleukin [IL]-1, IL-4, IL-6, tumor necrosis factor alpha, and so on), variously involved in tissue regeneration, and have a significant role on cellular differentiation (36, 37). Pure platelet-rich plasma, leukocyte platelet-rich plasma, pure platelet-rich fibrin, and leukocyte platelet-rich fibrin are 4 types of platelet concentrates that have been used extensively for regeneration purposes (38). PRP is the first generation of platelet concentrates, which can be made through either 1- or 2-step centrifugation of the anticoagulant periph-

eral whole blood (39). The platelets are inactive and in a round shape in PRP form so that they can only be activated after injection to the injury site and upon exposure to injured collagen fibers. PRP can be manually activated by the addition of bovine thrombin and CaCl_2 into the solution; thus, platelet gel (PG) is formed. The platelets in the PG are active in nature and release their growth factors upon implantation in the injured site (40). However, the complex production procedure, activation, and sudden fibrin polymerization are disadvantages of PRP and its activated form, PG (36). In addition, bovine thrombin as an activator can irritate immune cells to release and expose antibodies to V and XI factors and thrombin, which adversely affect the coagulation process (36, 41). In 2001, Choukroun et al (14) suggested a second generation of platelets called PRF (42, 43). This gel form material is harvested by a single centrifugation of anticoagulant-free blood and does not require activation (42, 44). Physiological thrombin available in PRF creates equilateral junctions in polymerized fibrin, which results in long-term growth factor release (up to 28 days) and a flexible fibrin network, which is an appropriate microenvironment for cell migration (36, 43). Thus, PRF is a preferable scaffold in regenerative endodontics and is initially used to accelerate tissue healing (45). Briefly, their advantage over PRP includes ease of preparation, and also there is no need for an anticoagulation material that results in an autogenic and natural substance (46, 47). During the degradation of PRP, large amounts of cytokines such as platelet-derived growth factor, transforming growth factor- β 1, and vascular endothelial growth factor are released, which reaches a maximum level on day 14 that is coincident with cell ingrowth (48). The secretion of platelet-derived growth factor and transforming growth factor beta 1 continues up to 28 days (47). The application of transforming growth factor beta 1 to odontoblasts in cultured tooth slices accelerated reactionary dentinogenesis (49). Also, the presence of leukocytes, cytokines, and few lymphocytes in PRF reduces infection and inflammation. Angiogenesis is increased because of the release of vascular endothelial growth factor, which plays an important role in revascularization (50). Despite the potential effectiveness of platelet

concentrates in promoting the regeneration of the dentin-pulp complex, scientific evidence is lacking. Platelet concentrates are not only a rich source for growth factors but also considered a biomimetic scaffold for endodontic tissue regeneration. PRF functional theory states that PRF stimulates stem cell proliferation and higher expressions of osteoprotegerin proteins and alkaline phosphatase. These proteins are usually identified as odontoblast differentiation markers (31).

Biodentine was used as a double seal calcium silicate material, which has a wide range of application and has a shorter setting time in comparison with MTA (51). Interestingly, it has been shown that Biodentine provokes immortalized murine pulp cell differentiation into odontoblastlike cells and stimulates biomineralization (52). This biomaterial has a reparative dentin synthesis capacity because it modulates transforming growth factor β -1 secretion by pulp cells (53) and causes minor discoloration compared with mineral trioxide aggregate (54, 55). Minimal discoloration was observed in all 4 cases (Figs. 1F, 3G, 4G, and 5H and J), which might be related to the biochemical interaction between Biodentine and PRF.

In previous studies, the tissue formed in root canals was fibrous connective and cementumlike tissues instead of a mature dentin-pulp complex. However, what is clinically important is the survival rate of the treated tooth in regenerative endodontic procedures (100%) when compared with other endodontic procedures such as apexogenesis (77%) (56). It has long been established that the principal objective of all endodontic treatments is to treat the symptoms of infection (57). Although this is evaluated based on a lack of pain, inflammation, and sinus tract as clinician-based outcomes, patient-based outcomes such as tooth survival and acceptable esthetics play a pivotal role in evaluating the overall results of endodontic procedures (57). In this case series, even though there were minor discolorations in all 4 cases, the treatment showed a resolution of symptoms. As Diogenes et al (57) recently reported, regenerative endodontic procedures are considered the first treatment option for cases of immature teeth with pulpal necrosis. Numerous reports indicated that regenerative endodontic procedure treatment outcomes are subject to considerable variations because of age, sex, and treatment variation (8). The American Association of Endodontist's recommendations for follow-up examinations indicate that the resolution of apical radiolucency should be observed between 6 and 12 months; this is evident in all cases (Figs. 1 and 3–5) (8). This is followed by evidence of apical closure (Figs. 1E, 3F, 4E and F, and 5E–J). The American Association of Endodontist's guidelines reported increased root width followed by root length between 12 and 24 months (8). However, Bose et al (56) reported that the highest percentage increase in root width was observed in follow-ups longer than 36 months. Indeed, although root lengthening was not consistently evident in all cases in this study, further long-term follow-ups (more than 36 months) are required to achieve a better results in terms of root lengthening.

Conclusion

Tissue regeneration with PRF in teeth with necrotic pulps and open apices occurred when a strict clinical protocol was followed. Further clinical trials will provide more evidence that PRF is an appropriate scaffold for pulp regeneration and the nature of the tissues formed within the root canal. Studies are needed to clarify the precise mechanism of action of PRF for dental pulp regeneration both *in vitro* and *in vivo*.

References

1. Bakhtiar H, Vatanpour M, Rayani A, et al. The plasma-rich in growth factor as a suitable matrix in regenerative endodontics: a case series. *N Y State Dent J* 2014;80:49–53.

2. Keswani D, Pandey RK. Revascularization of an immature tooth with a necrotic pulp using platelet-rich fibrin: a case report. *Int Endod J* 2013;46:1096–104.
3. Yassen GH, Platt JA. The effect of nonsetting calcium hydroxide on root fracture and mechanical properties of radicular dentine: a systematic review. *Int Endod J* 2013;46:112–8.
4. Yassen GH, Eckert GJ, Platt JA. Effect of intracanal medicaments used in endodontic regeneration procedures on microhardness and chemical structure of dentin. *Restor Dent Endod* 2015;40:104–12.
5. Yassen GH, Sabrah AH, Eckert GJ, Platt JA. Effect of different endodontic regeneration protocols on wettability, roughness, and chemical composition of surface dentin. *J Endod* 2015;41:956–60.
6. Nosrat A, Seifi A, Asgary S. Regenerative endodontic treatment (revascularization) for necrotic immature permanent molars: a review and report of two cases with a new biomaterial. *J Endod* 2011;37:562–7.
7. Nosrat A, Ryul Kim J, Verma P, S Chand P. Tissue engineering considerations in dental pulp regeneration. *Iran Endod J* 2014;9:30–9.
8. Law AS. Considerations for regeneration procedures. *Pediatr Dent* 2013;35:141–52.
9. Banchs F, Trope M. Revascularization of immature permanent teeth with apical periodontitis: new treatment protocol? *J Endod* 2004;30:196–200.
10. Bezgin T, Yilmaz AD, Celik BN, Sonmez H. Concentrated platelet-rich plasma used in root canal revascularization: 2 case reports. *Int Endod J* 2014;47:41–9.
11. Jadhav GR, Shah N, Logani A. Platelet-rich plasma supplemented revascularization of an immature tooth associated with a periapical lesion in a 40-year-old man. *Case Rep Dent* 2014;2014:479584.
12. Yeom KH, Ariyoshi W, Okinaga T, et al. Platelet-rich plasma enhances the differentiation of dental pulp progenitor cells into odontoblasts. *Int Endod J* 2016;49:271–8.
13. He L, Lin Y, Hu X, et al. A comparative study of platelet-rich fibrin (PRF) and platelet-rich plasma (PRP) on the effect of proliferation and differentiation of rat osteoblasts *in vitro*. *Oral Surg Oral Med Oral Pathol Oral Radiol Endod* 2009;108:707–13.
14. Choukroun J, Adda F, Schoeffler C, Vervelle A. Une opportunit  en parodontologie: le PRF. *Implantodontie* 2001;42:55–62. e62.
15. American Association of Endodontists. AAE Clinical Considerations for a Regenerative Procedure. Available at: https://www.aae.org/uploadedfiles/publications_and_research/research/currentregenerativeendodonticconsiderations.pdf. Accessed December 6th 2016.
16. Shen J, James AW, Zhang X, et al. Novel Wnt regulator NEL-like molecule-1 antagonizes adipogenesis and augments osteogenesis induced by bone morphogenetic protein 2. *Am J Pathol* 2016;186:419–34.
17. European Society of Endodontology position statement: revitalisation procedures. *Int Endod J* 2016;49:717–23.
18. Trevino EG, Patwardhan AN, Henry MA, et al. Effect of irrigants on the survival of human stem cells of the apical papilla in a platelet-rich plasma scaffold in human root tips. *J Endod* 2011;37:1109–15.
19. Fouad AF, Verma P. Healing after regenerative procedures with and without pulpal infection. *J Endod* 2014;40(Suppl):S58–64.
20. Thibodeau B, Trope M. Pulp revascularization of a necrotic infected immature permanent tooth: case report and review of the literature. *Pediatr Dent* 2007;29:47–50.
21. Alkahtani A, Alkahtany SM, Anil S. An *in vitro* evaluation of the cytotoxicity of varying concentrations of sodium hypochlorite on human mesenchymal stem cells. *J Contemp Dent Pract* 2014;15:473–81.
22. Yi T, Jun CM, Kim SJ, Yun JH. Evaluation of *in vivo* osteogenic potential of bone morphogenetic protein 2-overexpressing human periodontal ligament stem cells combined with biphasic calcium phosphate block scaffolds in a critical-size bone defect model. *Tissue Eng Part A* 2016;22:501–12.
23. Diogenes A, Henry MA, Teixeira FB, Hargreaves KM. An update on clinical regenerative endodontics. *Endod Topics* 2013;28:2–23.
24. Yassen GH, Vail MM, Chu TG, Platt JA. The effect of medicaments used in endodontic regeneration on root fracture and microhardness of radicular dentine. *Int Endod J* 2013;46:688–95.
25. Ruparel NB, Teixeira F, Ferraz CC, et al. Direct effect of intracanal medicaments on survival of stem cells of the apical papilla. *J Endod* 2012;38:1372–5.
26. Netea MG, Van der Graaf C, Van der Meer JW, Kullberg BJ. Recognition of fungal pathogens by Toll-like receptors. *Eur J Clin Microbiol Infect Dis* 2004;23:672–6.
27. Sabrah AH, Yassen GH, Spolnik KJ, et al. Evaluation of residual antibacterial effect of human radicular dentin treated with triple and double antibiotic pastes. *J Endod* 2015;41:1081–4.
28. Torabinejad M, Milan M, Shabahang S, et al. Histologic examination of teeth with necrotic pulps and periapical lesions treated with 2 scaffolds: an animal investigation. *J Endod* 2015;41:846–52.
29. Thibodeau B, Teixeira F, Yamauchi M, et al. Pulp revascularization of immature dog teeth with apical periodontitis. *J Endod* 2007;33:680–9.

30. Lovelace TW, Henry MA, Hargreaves KM, Diogenes A. Evaluation of the delivery of mesenchymal stem cells into the root canal space of necrotic immature teeth after clinical regenerative endodontic procedure. *J Endod* 2011;37:133–8.
31. Shivashankar VY, Johns DA, Vidyanath S, Kumar MR. Platelet rich fibrin in the revitalization of tooth with necrotic pulp and open apex. *J Conserv Dent* 2012;15:395–8.
32. Hargreaves KM, Giesler T, Henry M, Wang Y. Regeneration potential of the young permanent tooth: what does the future hold? *J Endod* 2008;34(Suppl):S51–6.
33. Yang Y, Ge Y, Chen G, et al. Hertwig's epithelial root sheath cells regulate osteogenic differentiation of dental follicle cells through the Wnt pathway. *Bone* 2014;63:158–65.
34. Andreasen JO, Kristerson L, Andreasen FM. Damage of the Hertwig's epithelial root sheath: effect upon root growth after autotransplantation of teeth in monkeys. *Endod Dent Traumatol* 1988;4:145–51.
35. Nevins A, Crespi P. A clinical study using the collagen gel Zyplast in endodontic treatment. *J Endod* 1998;24:610–3.
36. Preeja C, Arun S. Platelet-rich fibrin: its role in periodontal regeneration. *Saudi J Dent Res* 2014;5:117–22.
37. Alsousou J, Ali A, Willett K, Harrison P. The role of platelet-rich plasma in tissue regeneration. *Platelets* 2013;24:173–82.
38. Del Corso M, Mazor Z, Rutkowski JL, Dohan Ehrenfest DM. The use of leukocyte- and platelet-rich fibrin during immediate postextractive implantation and loading for the esthetic replacement of a fractured maxillary central incisor. *J Oral Implantol* 2012;38:181–7.
39. Nagaveni NB, Kumari KN, Poornima P, Reddy V. Management of an endo-perio lesion in an immature tooth using autologous platelet-rich fibrin: a case report. *J Indian Soc Pedod Prev Dent* 2015;33:69–73.
40. Lolato A, Bucchi C, Taschieri S, et al. Platelet concentrates for revitalization of immature necrotic teeth: a systematic review of the clinical studies. *Platelets* 2016;27:383–92.
41. Borie E, Olivi DG, Orsi IA, et al. Platelet-rich fibrin application in dentistry: a literature review. *Int J Clin Exp Med* 2015;8:7922–9.
42. Ji B, Sheng L, Chen G, et al. The combination use of platelet-rich fibrin and treated dentin matrix for tooth root regeneration by cell homing. *Tissue Eng Part A* 2015;21:26–34.
43. Chang YC, Zhao JH. Effects of platelet-rich fibrin on human periodontal ligament fibroblasts and application for periodontal infrabony defects. *Aust Dent J* 2011;56:365–71.
44. Woo SM, Kim WJ, Lim HS, et al. Combination of mineral trioxide aggregate and platelet-rich fibrin promotes the odontoblastic differentiation and mineralization of human dental pulp cells via BMP/Smad signaling pathway. *J Endod* 2016;42:82–8.
45. Sunitha Raja V, Munirathnam Naidu E. Platelet-rich fibrin: evolution of a second-generation platelet concentrate. *Indian J Dent Res* 2008;19:42–6.
46. Hiremath H, Saikalyan S, Kulkarni SS, Hiremath V. Second-generation platelet concentrate (PRF) as a pulpotomy medicament in a permanent molar with pulpitis: a case report. *Int Endod J* 2012;45:105–12.
47. Mishra N, Narang I, Mittal N. Platelet-rich fibrin-mediated revitalization of immature necrotic tooth. *Contemp Clin Dent* 2013;4:412–5.
48. Keswani D, Pandey RK, Ansari A, Gupta S. Comparative evaluation of platelet-rich fibrin and mineral trioxide aggregate as pulpotomy agents in permanent teeth with incomplete root development: a randomized controlled trial. *J Endod* 2014;40:599–605.
49. Smith AJ, Murray PE, Sloan AJ, et al. Trans-dentinal stimulation of tertiary dentinogenesis. *Adv Dent Res* 2001;15:51–4.
50. Toffler M, Holtzclaw D, Toscano N, et al. Introducing Choukroun's platelet rich fibrin (PRF) to the reconstructive surgery milieu. *J Implant Adv Clin Dent* 2009;1:21–31.
51. Malkondu O, Karapinar Kazandag M, Kazazoglu E. A review on biodentine, a contemporary dentine replacement and repair material. *Biomed Res Int* 2014;2014:160951.
52. Zanini M, Sautier JM, Berdal A, Simon S. Biodentine induces immortalized murine pulp cell differentiation into odontoblast-like cells and stimulates biomineralization. *J Endod* 2012;38:1220–6.
53. Rathinam E, Rajasekharan S, Chitturi RT, et al. Gene expression profiling and molecular signaling of dental pulp cells in response to tricalcium silicate cements: a systematic review. *J Endod* 2015;41:1805–17.
54. Shokouhinejad N, Nekoofar MH, Pirmoazen S, et al. Evaluation and comparison of occurrence of tooth discoloration after the application of various calcium silicate-based cements: an *ex vivo* study. *J Endod* 2016;42:140–4.
55. Kohli MR, Yamaguchi M, Setzer FC, Karabucak B. Spectrophotometric analysis of coronal tooth discoloration induced by various bioceramic cements and other endodontic materials. *J Endod* 2015;41:1862–6.
56. Bose R, Nummikoski P, Hargreaves K. A retrospective evaluation of radiographic outcomes in immature teeth with necrotic root canal systems treated with regenerative endodontic procedures. *J Endod* 2009;35:1343–9.
57. Diogenes A, Ruparel NB, Shiloah Y, Hargreaves KM. Regenerative endodontics: a way forward. *J Am Dent Assoc* 2016;147:372–80.